



Percutaneous cervical stabilization using the WSH Cervical B-Twin

WSH Cervical B-Twin tekniği ile perkütan servikal stabilizasyon

Won-Chul Choi, M.D., Sang-Ho Lee, M.D., PhD., Yong Ahn, M.D., Seungcheol Lee, M.D.,
Byung Kwan Choi, M.D., PhD., Song-Woo Shin, PhD.

Department of Neurosurgery, Wooridul Spine Hospital, Seoul, Korea

Objectives: Percutaneous endoscopic cervical discectomy is an effective minimally invasive procedure for cervical soft disc herniation. However, this procedure cannot be applied in patients with cervical disc herniation accompanied by segmental instability. Recently developed WSH Cervical B-Twin can be used as an interbody spacer to achieve stability without open discectomy and fusion. The aim of this study was to present the surgical technique of percutaneous cervical stabilization with the use of the WSH Cervical B-Twin and to evaluate its results.

Patients and methods: Seventeen consecutive patients (11 males, 6 females; mean age 48.8 years; range 30 to 65 years) underwent the index surgery between March 2001 and August 2004. The mean duration of symptoms was 38.8 months (range 6 to 120 months). Preoperative evaluations were made using computed tomography, magnetic resonance imaging, dynamic X-rays, and provocative discography. All the procedures were performed under local anesthesia and on an outpatient basis. Neck pain was evaluated by the visual analog scale (VAS). The mean follow-up was 26.6 months (range 5 to 46 months).

Results: The mean hospital stay was 12 hours. The mean VAS score for neck pain significantly decreased ($p<0.001$). A favorable outcome was achieved in 13 patients (76.5%) with recovery rates ranging from 40% to 90%. Four patients (23.5%) had no symptomatic improvement. Two patients (11.8%) required open surgery because of incomplete decompression. No permanent neurological deficits, infections, or procedure-related complications were encountered.

Conclusion: In selected cases, percutaneous cervical stabilization using the WSH Cervical B-Twin is a safe and effective procedure for cervical disc herniation with segmental instability.

Key words: Cervical vertebrae; decompression, surgical/methods; discectomy, percutaneous/methods; intervertebral disk displacement/surgery; treatment outcome.

Amaç: Perkütan endoskopik servikal diskektomi servikal disk herniasyonunda etkili bir minimal invaziv cerrahi prosedürdür. Ancak, bu yöntem, servikal disk herniasyonu yanı sıra servikal instabilite olan hastalarda uygulanamamaktadır. Yeni geliştirilmiş olan WSH Cervical B-Twin (interbody spacer) ile, açık diskektomi ve füzyona başvurmaksızın servikal stabilite sağlanabilmektedir. Bu çalışmada, WSH Cervical B-Twin kullanılarak yapılan perkütan servikal stabilizasyon tekniği ve sonuçları sunuldu.

Hastalar ve yöntemler: Çalışmaya, Mart 2001-Ağustos 2004 arasında indeks cerrahi uygulanan 17 ardışık hasta (11 erkek, 6 kadın; ort. yaş 48.8; dağılım 30-65) alındı. Ortalama semptom süresi 38.8 ay (dağılım 6-120 ay) idi. Ameliyat öncesi değerlendirmelerde bilgisayarlı tomografi, manyetik rezonans görüntüleme, dinamik radyografiler ve provokatif diskografi kullanıldı. Tüm işlemler local anestezi altında ve poliklinik koşullarında yapıldı. Boyun ağrısı görsel analog skala (GAS) ile değerlendirildi. Ortalama izlem süresi 26.6 ay (dağılım 5-46 ay) idi.

Bulgular: Hastanede kalış süresi ortalaması 12 saat idi. Boyun ağrısı için ortalama GAS skoru anlamlı derecede düşük bulundu ($p<0.001$). On üç hastada (%76.5) %40 ile %90 arasında iyileşme ile iyi sonuç alındı. Dört hastada (%23.5) semptomatik düzelme görülmedi. İki hastada (%11.8), yetersiz dekompresyon nedeniyle açık cerrahi gerekti. Hiçbir hastada nörolojik defisit, enfeksiyon ve teknikle ilgili komplikasyona rastlanmadı.

Sonuç: Seçilmiş hastalarda, WSH Cervical B-Twin kullanılarak yapılan perkütan servikal stabilizasyon, beraberinde segmental stabilite olan servikal disk herniasyonlarında güvenli ve etkili bir tekniktir.

Anahtar sözcükler: Servikal vertebra; dekompresyon, cerrahi/yöntem; diskektomi, perkütan/yöntem; intervertebral disk displasmanı/cerrahi; tedavi sonucu.

Cervical disc herniation is a major cause of neck, shoulder, and upper limb pain. Anterior cervical discectomy and fusion (ACDF) has been considered the standard treatment for cervical disc herniation.^[1] Since Tajima et al.,^[2] who were the first to report cervical percutaneous discectomy in 1989, there has been a remarkable evolution of various minimally invasive techniques for cervical disc disease. These include chemonucleolysis using chymopapain,^[3] automated percutaneous cervical discectomy (APCD),^[4-6] chemonucleolysis followed by APCD,^[7] and laser percutaneous cervical decompression,^[8-14] all of which are well-established.

Currently, percutaneous endoscopic cervical discectomy (PECD) is considered a good alternative to anterior cervical discectomy and fusion for cervical disc herniation.^[9,12-14] However, this procedure cannot be applied in case of segmental instability or other discogenic pain syndromes. Recently developed WSH Cervical B-Twin (Disc-O-Tech, Israel) can be used as an interbody spacer to achieve stability without open discectomy and fusion (Fig. 1). The aim of this study was to present the surgical technique of percutaneous cervical stabilization with the use of the WSH Cervical B-Twin and to evaluate its clinical outcomes.

PATIENTS AND METHODS

This retrospective analysis included 17 consecutive patients who underwent the index surgery at the authors' hospital between March 2001 and August 2004. There were 11 males and six females with a mean age of 48.8 years (range 30 to 65 years). The mean duration of symptoms was 38.8 months

TABLE I

Preoperative evaluations and indications	
	Check point
CT and MRI	Disc extrusion
Dynamic X-ray	Angular instability
Provocative discography	Concordant pain provocation
Symptoms	Axial pain like headache, neck and shoulder pain with arm radiculopathy

(range 6 to 120 months). Preoperative evaluations were made using computed tomography (CT), magnetic resonance imaging (MRI), dynamic X-ray, and provocative discography (Table I).

The patients were enrolled into the study depending on the presence of (i) cervical disc herniation with segmental instability (kyphosis at flexion radiography) confirmed by X-ray, CT and/or MRI, and (ii) cervicoencephalic symptoms due to soft cervical disk herniation diagnosed by discography. Contraindications were as follows: cervical spondylotic myelopathy, a sequestered disc fragment, definite segmental instability, advanced spondylosis with narrowing disc space, and neurologic or vascular pathologies mimicking a herniated disc.

Neck pain was evaluated by the 10-point visual analog scale (VAS). Preoperatively, all the patients were assumed to have the highest VAS score. A difference of at least 4 points (recovery by 40%) from the preoperative VAS score was defined as a favorable outcome. The mean follow-up period was 26.6 months (range 5 to 46 months). Statistical analyses were made using the Wilcoxon's signed-rank test.

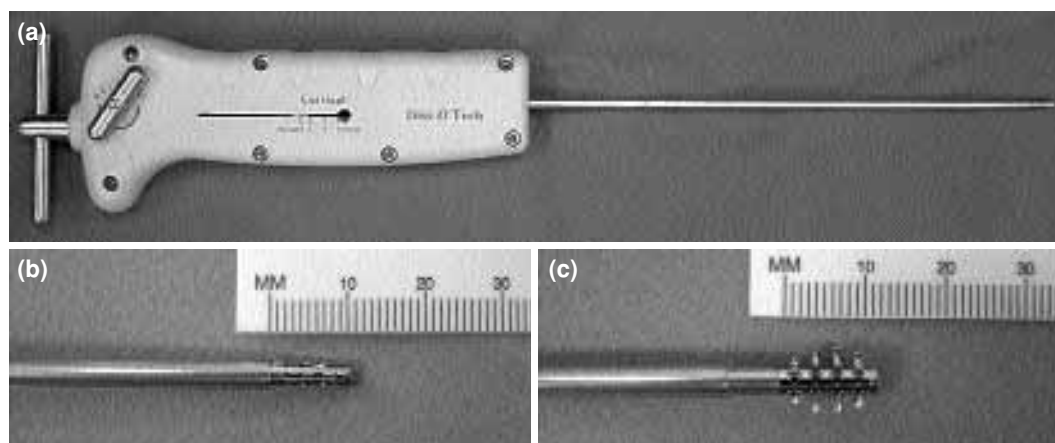


Fig. 1. (a) The single-use delivery system of WSH Cervical B-Twin, **(b)** the reduced form, and **(c)** the expanded form.

Surgical technique

All the procedures were performed under local anesthesia (1% lidocaine) on an outpatient basis. Preoperatively, antibiotics (usually 1.0 g of cefazolin) and sedatives were given. The patient was placed in a supine position with the neck mildly extended on a radiolucent table. The skin and subcutaneous tissues were infiltrated with 1% lidocaine (Xylocaine®).

The surgeon gently pushes the trachea or larynx toward the opposite side using the index and middle fingers, then applies a firm pressure in the space between the muscle and the trachea, pointing toward the vertebral space. The trachea and larynx are displaced medially and the carotid artery laterally. An 18 G needle is then inserted into the disc space through the space between the tracheoesophagus and the carotid artery. To identify the type of herniation or annular tears, intraoperative discography is performed with a contrast media (up to 0.5 ml of Telebrix®) mixed with indigo carmine.

A guidewire is passed through the needle channel into the disc. After the removal of the needle, a 3-mm skin incision is made. To dilate the tract, a series of cannulas (1 to 5 mm) are sequentially passed over the guidewire and introduced toward the annulus under fluoroscope guidance. The final working cannula is inserted into the disc space after the anterior annulus is cut by an annulotomy-trepine. The nucleus is removed with the use of microforceps up to the posterior margin of the vertebral body. The intradiscal space is irrigated continuously with cefazolin-containing saline through an irrigation channel in the microforceps.

After manual discectomy, the tissue near or inside the hernia mass is ablated using the laser-assisted spinal endoscope (LASE; Clarus, USA), which integrates Ho:YAG laser, endoscopy, illumination, and irrigation. The intervention is halted when the LASE faces no resistance in the posterior part of the disc and the hernia mass is no longer seen inside the posterior longitudinal ligament.

The cartilagenous end plate is exposed and checked under endoscopic visualization. Preparation of the end plate is made with the use of minicurettes. The bulk of the posterior nucleus pulposus is removed. Under fluoroscopic guidance, the reduced implant is introduced into the

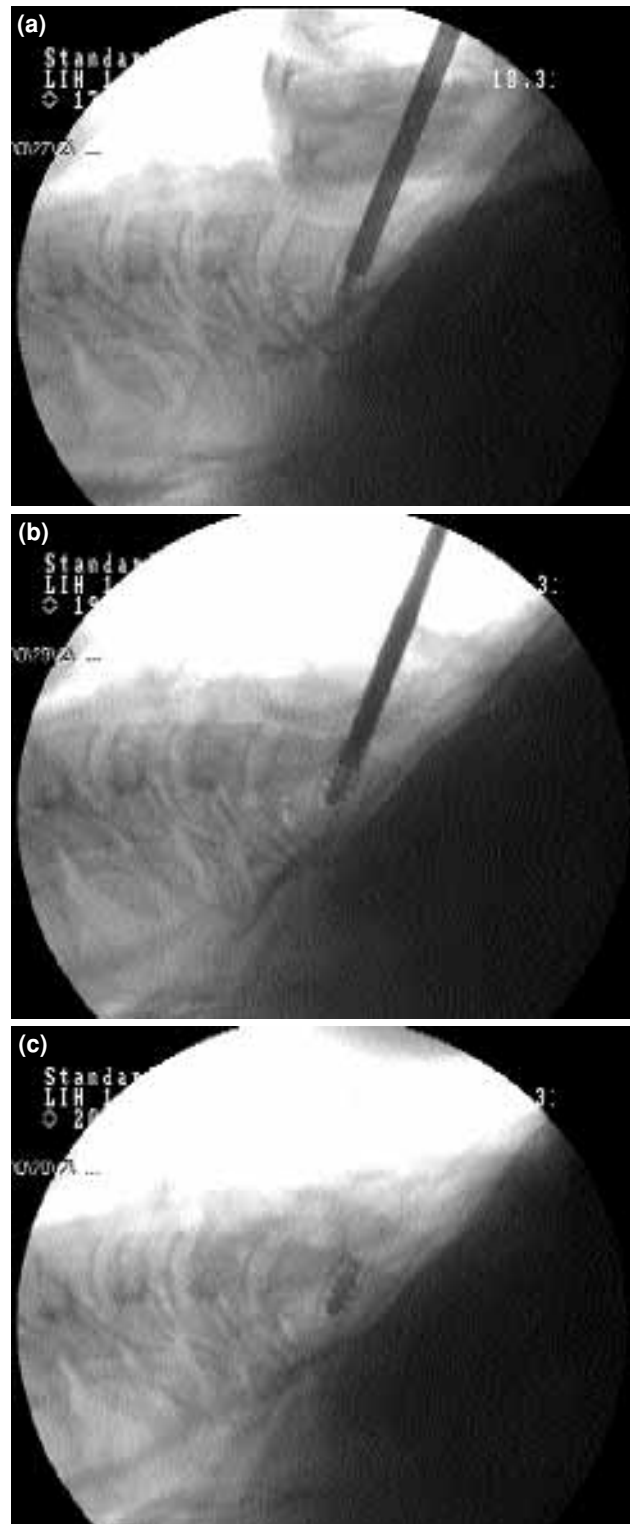


Fig. 2. (a) Intraoperative C-arm view of the WSH Cervical B-Twin. Under fluoroscopic guidance, the reduced implant is introduced into the intervertebral disc space using the single-use delivery system. (b) Once in position, it is expanded with manual rotation of the handle. (c) After its expansion, the implant is released from the delivery system.

intervertebral disc space using the single-use delivery system (Fig. 2a). Once in position, it is expanded with manual rotation of the handle (Fig. 2b), and the implant is released from the delivery system (Fig. 2c). It can be applied as stand-alone. The position should be carefully selected before the expansion procedure. Pulling and pushing of the device is not recommended after detachment.

At the end of the operation, profuse irrigation is performed with antibiotic-containing saline solution. After the instrument is removed, slight finger compression can be applied on the surgical area for a short time to prevent hematoma formation. Only one stitch is required to close the puncture site and the wound is covered with a bandaid.

After three hours of observation, the patient is allowed to go home unless there is a complication. Postoperative antibiotics and analgesics are recommended peroral for three to ten days. A cervical collar is recommended for 3-14 days, depending on the patient's condition.

RESULTS

The mean hospital stay was 12 hours. The mean VAS score for neck pain significantly decreased to 4.5 ($p < 0.001$). A favorable outcome was achieved

in 13 patients (76.5%) with recovery rates ranging from 40% to 90%. Four patients (23.5%) had no symptomatic improvement. During the follow-up period, conversion to open surgery (anterior cervical discectomy and fusion) was required in two patients (11.8%) because of incomplete decompression. No permanent neurological deficits or infections were encountered.

DISCUSSION

Since the early 1950s, ACDF, which involves removal of the intervertebral disc and insertion of a bone graft under general anesthesia, has been regarded as the gold standard treatment for cervical disc herniations and cervical spondylosis.^[1] However, this open surgery may be associated with damage to anterior structures like the anterior annulus fibrosus, anterior longitudinal ligament, longus coli muscle, and possibly anterior cortical bone, all of which have important roles in maintaining cervical stability. In addition, this surgery usually requires entrance into the spinal canal, with the accompanying risk of such complications as epidural bleeding, perineural fibrosis, transient or permanent myelopathy, graft-related problems (e.g. donor site morbidity, painful pseudarthrosis, graft extrusion or angular collapse,

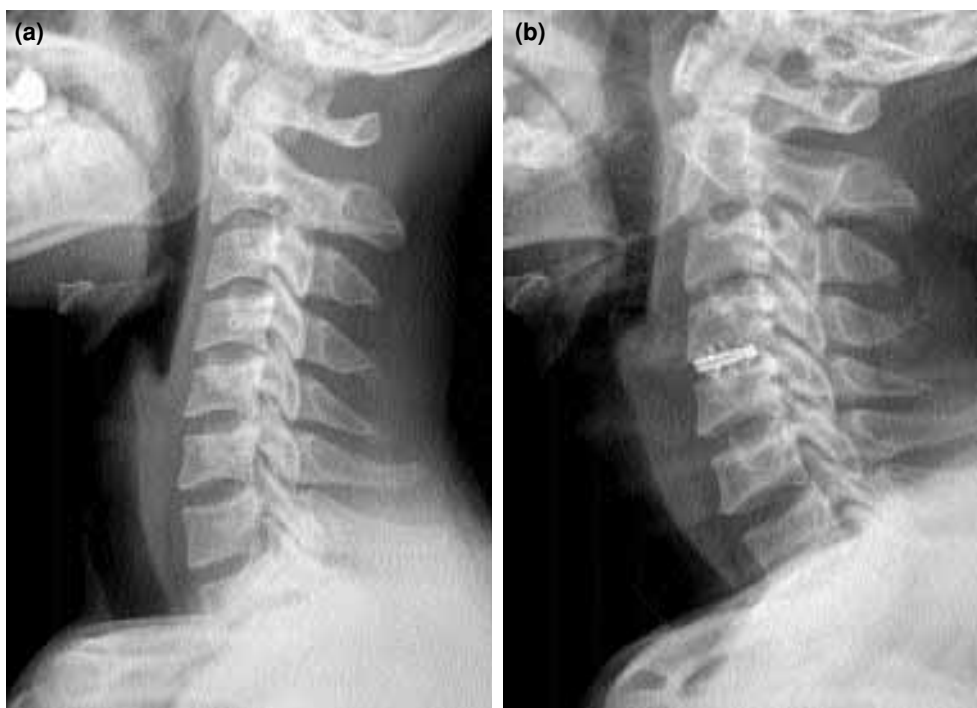


Fig. 3. Comparison of (a) preoperative and (b) postoperative X-rays showing improvement in lordotic alignment after surgery.

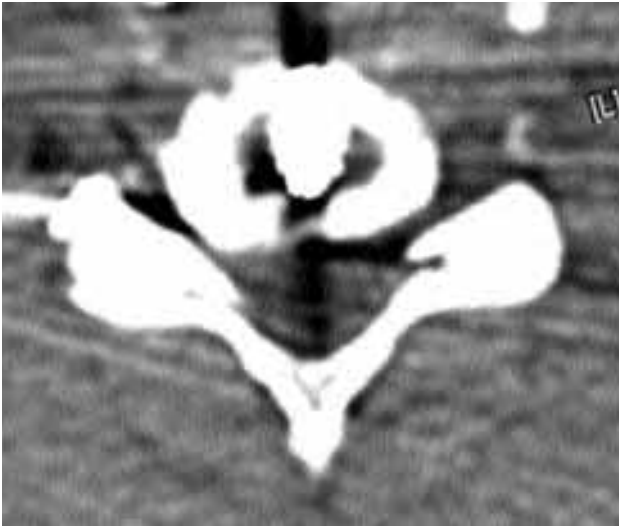


Fig. 4. A postoperative CT scan showing the proper positioning of the implant.

kyphotic deformity, graft impaction into the body), dysphasia, and hoarseness (e.g. temporary or permanent vocal cord paresis).^[15-21]

The specially designed WSH Cervical B-Twin can be applied by a less invasive technique, requiring minimal tissue dissection for spinal stability. Since the implant is introduced into the intervertebral space in a reduced form, it requires an opening of only less than 5 mm. Following the insertion of the delivery system, the implant is expanded to its final form, which is sufficient to maintain the disc height.

In this study, the authors propose an alternative technique to ACDF for cervical disc herniation with segmental instability and present their experience with percutaneous cervical stabilization under local anesthesia. This minimally invasive procedure can preserve anterior structures and stability, prevent postoperative kyphotic changes, and minimize approach-related complications. The procedure also provides an excellent cosmetic effect, reduces the operation time and hospital stay, and allows a more rapid return of the patient to normal daily activities. In case of failure, it does not preclude subsequent open surgeries.

The majority of the patients had remarkable relief of pain after the procedure. The preoperative kyphotic alignment improved postoperatively (Fig. 3a, b). The position of the implant was confirmed by CT scans (Fig. 4). No procedure-related complications occurred. The clinical results were

comparable to those obtained by open discectomy and fusion.

In conclusion, percutaneous cervical stabilization using the WSH Cervical B-Twin is an outpatient surgery and proved to be as safe and efficacious as open ACDF in selected patients. Although our series is too small to draw definitive conclusions, percutaneous cervical stabilization will be a promising technique for cervical disc herniation with segmental instability.

REFERENCES

1. Cloward RB. The anterior approach for removal of ruptured cervical disks. *J Neurosurg* 1958;15:602-17.
2. Tajima T, Sakamoto H, Yamakawa H. Discectomy cervicale percutanee. *Revue Med Orthoped* 1989;17:7-10.
3. Richaud J, Lazorthes Y, Verdie JC, Bonafe A. Chemonucleolysis for herniated cervical disc. *Acta Neurochir* 1988;91:116-9.
4. Courtheoux F, Theron J. Automated percutaneous nucleotomy in the treatment of cervicobrachial neuralgia due to disc herniation. *J Neuroradiol* 1992;19:211-6.
5. Zhou YC, Zhou YQ, Wang CY. Percutaneous cervical discectomy for treating cervical disc herniation-a report of 12 cases. *J Tongji Med Univ* 1994;14:110-3.
6. Bonaldi G, Minonzio G, Belloni G, Dorizzi A, Fachinetti P, Marra A, et al. Percutaneous cervical discectomy: preliminary experience. *Neuroradiology* 1994;36:483-6.
7. Hoogland T, Scheckenbach C. Low-dose chemonucleolysis combined with percutaneous nucleotomy in herniated cervical disks. *J Spinal Disord* 1995;8:228-32.
8. Siebert W. Percutaneous laser discectomy of cervical discs: preliminary clinical results. *J Clin Laser Med Surg* 1995;13:205-7.
9. Lee SH, Gastambide D. Perkutane endoskopische Diskotomie der Halswirbelsaule. In: Pfeil J, Siebert W, Janousek A, Josten C, editors. *Minimal-invasive Verfahren in der Orthopadie und Traumatologie*. Berlin: Springer-Verlag; 2000. p. 41-61.
10. Chiu JC, Clifford TJ, Greenspan M, Richley RC, Lohman G, Sison RB. Percutaneous microdecompressive endoscopic cervical discectomy with laser thermodiskoplasty. *Mt Sinai J Med* 2000;67:278-82.
11. Knight MT, Goswami A, Patko JT. Cervical percutaneous laser disc decompression: preliminary results of an ongoing prospective outcome study. *J Clin Laser Med Surg* 2001;19:3-8.
12. Lee SH. Percutaneous cervical discectomy with forceps and endoscopic Ho:YAG laser. In: Gerber BE, Knight M, Siebert WE, editors. *Lasers in the musculoskeletal system*. Berlin: Springer-Verlag; 2001. p. 292-302.
13. Gastambide D, Peyrou P, Lee SH. Percutaneous cervical discectomy. In: Bentley G, Bohler N, Dorfmann H, editors. *Surgical techniques in orthopaedics and trau-*

- matology. Paris: Elsevier; 2004. p. 55-095-A-10.
14. Ahn Y, Lee SH, Lee SC, Shin SW, Chung SE. Factors predicting excellent outcome of percutaneous cervical discectomy: analysis of 111 consecutive cases. *Neuroradiology* 2004;46:378-84.
 15. Brodke DS, Zdeblick TA. Modified Smith-Robinson procedure for anterior cervical discectomy and fusion. *Spine* 1992;17(10 Suppl):S427-30.
 16. Bulger RF, Rejowski JE, Beatty RA. Vocal cord paralysis associated with anterior cervical fusion: considerations for prevention and treatment. *J Neurosurg* 1985; 62:657-61.
 17. Clements DH, O'Leary PF. Anterior cervical discectomy and fusion. *Spine* 1990;15:1023-5.
 18. Flynn TB. Neurologic complications of anterior cervical interbody fusion. *Spine* 1982;7:536-9.
 19. Kadoya S, Nakamura T, Kwak R. A microsurgical anterior osteophyctomy for cervical spondylotic myelopathy. *Spine* 1984;9:437-41.
 20. Lunsford LD, Bissonette DJ, Jannetta PJ, Sheptak PE, Zorub DS. Anterior surgery for cervical disc disease. Part 1: Treatment of lateral cervical disc herniation in 253 cases. *J Neurosurg* 1980;53:1-11.
 21. Thorell W, Cooper J, Hellbusch L, Leibrock L. The long-term clinical outcome of patients undergoing anterior cervical discectomy with and without intervertebral bone graft placement. *Neurosurgery* 1998; 43:268-73.