



## Comparison of tension band wiring and plate fixation in Mayo type 2A olecranon fractures

Ceyhun Çağlar, MD<sup>1</sup>, Serhat Akçaalan, MD<sup>1</sup>, Halil İbrahim Özasan, MD<sup>1</sup>,  
Hilal Yağar, MD<sup>2</sup>, Mahmut Uğurlu, MD<sup>3</sup>

<sup>1</sup>Department of Orthopedics and Traumatology, Ankara City Hospital, Ankara, Turkey

<sup>2</sup>Department of Orthopedics and Traumatology, Yozgat City Hospital, Yozgat, Turkey

<sup>3</sup>Department of Orthopedics and Traumatology, Ankara Yıldırım Beyazıt University, Ankara, Turkey

Olecranon fractures are one of the most common elbow fractures in adults and also constitute approximately 8 to 10% of all upper limb fractures.<sup>[1,2]</sup> Simple transverse olecranon fractures are the most common pattern.<sup>[3]</sup> These fractures generally show a bimodal distribution; they are seen after high-energy trauma in young patients and after simple falls in older patients due to poor bone quality.<sup>[4]</sup> Due to the tension of the triceps brachii muscle and tendon, many olecranon fractures are displaced and the chance of conservative treatment is therefore low. To date, many different procedures have been defined in the surgical treatment of olecranon fractures, and the most preferred procedures by surgeons are tension band wiring (TBW) and plate fixation (PF). Tension band wiring is a simple and low-cost procedure and so it is considered the gold standard by many authors.<sup>[5]</sup> Functional results are satisfactory in the

Received: May 12, 2020

Accepted: July 20, 2020

Published online: January 06, 2021

**Correspondence:** Ceyhun Çağlar, MD. Ankara Şehir Hastanesi Ortopedi ve Travmatoloji Kliniği, 06800 Çankaya, Ankara, Türkiye.

E-mail: ceyhun.caglar@hotmail.com

Doi: 10.5606/ehc.2021.75812

**Citation:** Çağlar C, Akçaalan S, Özasan H, Yağar H, Uğurlu M. Comparison of tension band wiring and plate fixation in Mayo type 2A olecranon fractures. Jt Dis Relat Surg 2021;32(1):85-92.

©2021 All right reserved by the Turkish Joint Diseases Foundation

This is an open access article under the terms of the Creative Commons Attribution-NonCommercial License, which permits use, distribution and reproduction in any medium, provided the original work is properly cited and is not used for commercial purposes (<http://creativecommons.org/licenses/by-nc/4.0/>).

### ABSTRACT

**Objectives:** This study aims to compare clinically and functionally patients who had previously undergone tension band wiring (TBW) or plate fixation (PF) procedure due to the diagnosis of Mayo type 2A olecranon fracture in our clinic.

**Patients and methods:** Data of 92 patients (51 males, 41 females; mean age 42.3±12.6 years; range, 16 to 75 years) operated on for olecranon fractures between January 2014 and December 2018 were recorded retrospectively. Forty-four patients received TBW and 48 patients received PF treatment. Their Disabilities of the Arm, Shoulder, and Hand (DASH) and Mayo scores and elbow range of motion (ROM) measurements were used for clinical and functional evaluations. Data including the time to return to work, revision rate, and follow-up time were also recorded.

**Results:** The mean follow-up time was 38.2±17.2 months. Patients returned to work in 9.2±4.1 weeks in the TBW group and 7.8±3.6 weeks in the PF group (p=0.279). The revision rate was 14% in the TBW group and 2% in the PF group (p=0.335). The mean DASH score was 10.0±1.8 in the TBW group and 7.7±1.2 in the PF group (p=0.001). The mean Mayo score was 84.0±9.3 in the TBW group and 88.3±9.1 in the PF group (p=0.049). For elbow flexion-extension ROM, 4° of difference was measured in favor of the PF group (p=0.043). Mean Mayo score, mean DASH score, and mean flexion-extension ROM values were statistically significantly different between the two groups.

**Conclusion:** Both surgical techniques are suitable and reliable in the treatment of olecranon fractures. Although TBW treatment is low-cost and simple to apply, its biggest disadvantage is a high rate of secondary surgery for implant removal due to irritation of the skin.

**Keywords:** Elbow surgery, Mayo classification, olecranon fixation, olecranon fracture, plate fixation, tension band wiring.

treatment of simple olecranon fractures, but there are limited indications in comminuted fractures.<sup>[6]</sup> In addition, high complication rates and secondary surgical requirements have been reported in some studies.<sup>[7-9]</sup> Therefore, many alternative treatment

procedures have been developed, such as shaped plates, intramedullary rods, precontoured plates, and tendon sutures.<sup>[10,11]</sup> As a result, PF with locking screws has been preferred most frequently as an alternative to TBW by surgeons. Plate fixation can be used safely for all olecranon fractures, particularly oblique and complex fractures. However, one of the disadvantages of PF is that it is a more expensive procedure compared to TBW.<sup>[12]</sup>

Different scales have been created to evaluate the functional results of olecranon fractures after surgery. The Disabilities of the Arm, Shoulder, and Hand (DASH) questionnaire evaluates daily living activities and all upper limb functionality. The Mayo score is focused on movement, pain, and elbow stability.<sup>[13]</sup>

In the absence of any complications after the surgical treatment of olecranon fractures, the results are satisfactory. Possible complications that may occur are nonunion, malunion, proximal migration of Kirschner (K)-wires, decreased range of motion (ROM) and posttraumatic osteoarthritis.<sup>[14]</sup>

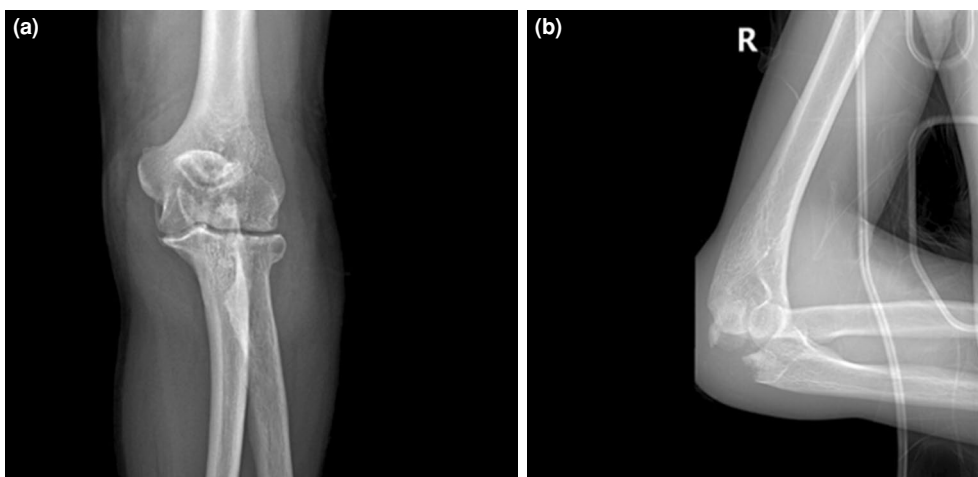
In this study, we aimed to compare clinically and functionally patients who had previously undergone TBW or PF procedure due to the diagnosis of Mayo type 2A olecranon fracture in our clinic.

## PATIENTS AND METHODS

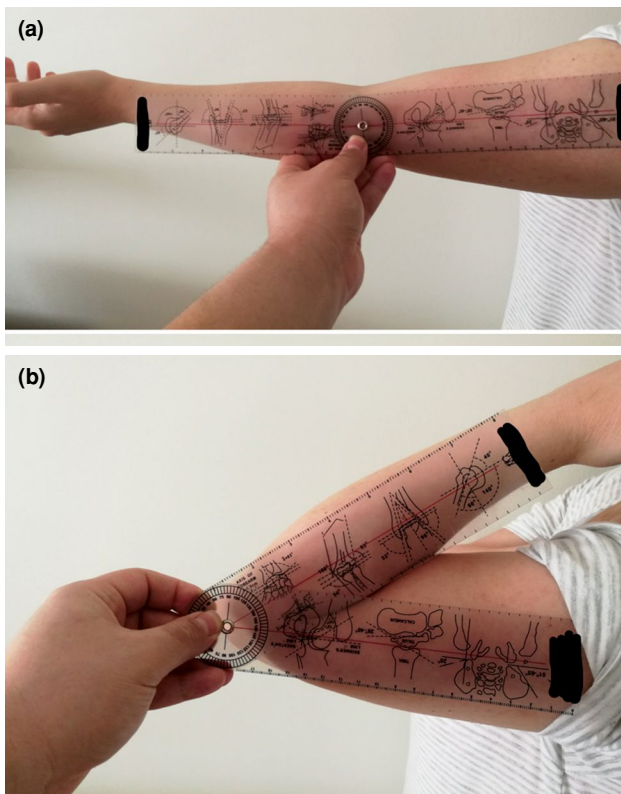
A total of 114 patients who underwent TBW or PF procedure due to Mayo type 2A olecranon fractures between January 2014 and December 2018 at Ankara Atatürk Training and Research Hospital, Department of Orthopedics and Traumatology were examined

retrospectively. The patients were evaluated in terms of age, sex, follow-up, and radiological, clinical, and functional outcomes. The study's inclusion criteria were as follows: Mayo type 2A olecranon fractures, more than 2 mm of joint displacement, and elbow extension loss. Patients with additional pathology in the same elbow, Monteggia equivalent fractures, tumor-related pathological fractures, open fractures, and revision surgery were excluded. Finally, 92 patients (51 males, 41 females; mean age  $42.3 \pm 12.6$  years; range, 16 to 75 years) who were eligible for the study were identified. All patients included in the study were operated on by the same surgeon. The study protocol was approved by the Ankara City Hospital Ethics Committee (approval: 07.05.2020-E1-20-511). A written informed consent was obtained from each patient. The study was conducted in accordance with the principles of the Declaration of Helsinki.

The patients were divided into two groups as those receiving TBW ( $n=44$ ) and those receiving PF ( $n=48$ ). Standard anteroposterior and lateral elbow radiography were taken before and after surgery for all patients (Figure 1a, b). All patients discharged after surgery were followed-up regularly. Time to return to work, follow-up times, and revision rates were recorded. The joint ROM values of all patients were measured one year after radiographic union by the same observer with a goniometer and results were recorded (Figure 2a, b). All measurement values were calculated by comparisons with the opposite elbow. Additionally, the functional scores of the patients were evaluated one year after radiographic union using the DASH and Mayo scores. The validated Turkish translations of both scales were used.



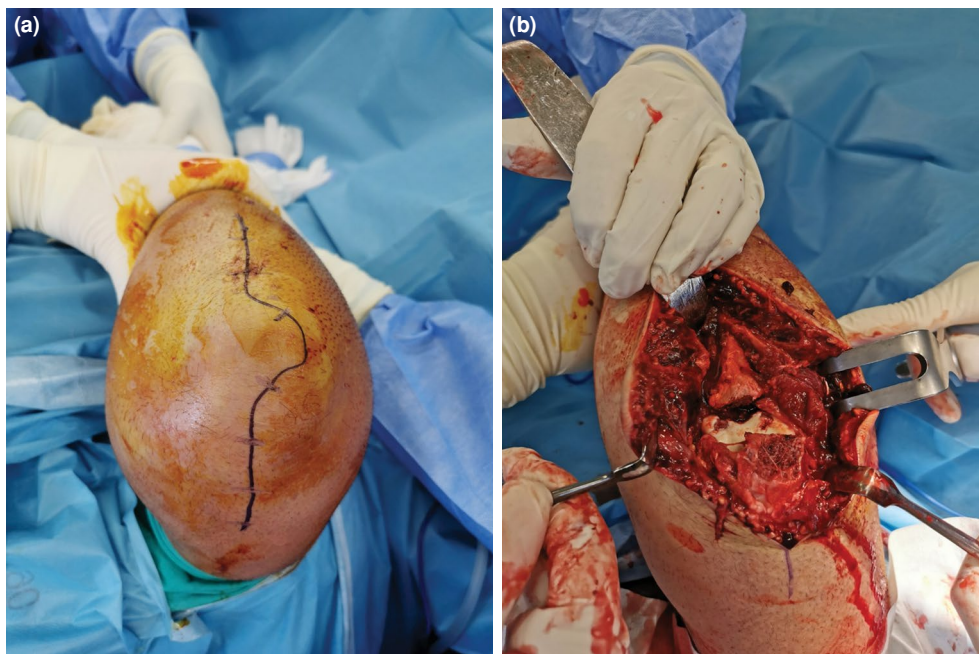
**FIGURE 1.** (a) Anteroposterior X-ray of Mayo type 2A olecranon fracture that occurred in a 23-year-old female patient. (b) Lateral X-ray of Mayo type 2A olecranon fracture that occurred in a 23-year-old female patient.



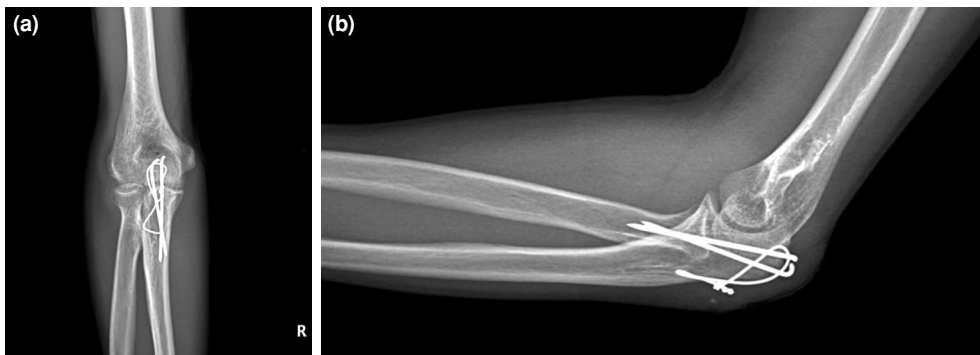
**FIGURE 2.** (a) Measurement of elbow extension degree of a 32-year-old female patient who underwent surgery due to olecranon fracture at one year after surgery with goniometer. (b) Measurement of elbow flexion degree of a 32-year-old female patient who underwent surgery due to olecranon fracture at one year after surgery with goniometer.

All patients were operated on in the supine position, using an arm table and a tourniquet for bleeding control. For all patients, a standard posterior longitudinal approach was sufficient for reduction and fixation (Figure 3a). In order to protect the ulnar nerve, the incision was performed by curving the radial side at the tip of the olecranon.

The working principle of TBW is to convert the tensile forces of the triceps brachii muscle into compression forces in the joint line. After the surgical incision is completed and the fracture is exposed (Figure 3b), fracture reduction is provided with a bone clamp. Two 1.6-mm K-wires are then placed antegrade from the olecranon towards the distal anterior cortex of the ulna, as perpendicular to the fracture line as possible. Neurovascular structures are preserved by placing the K-wires as distal as possible to the coronoid process.<sup>[15]</sup> A hole is drilled with a 2-mm drill approximately 4 cm distal to the fracture line. Then, a 1-mm metal wire is passed through this hole, placed towards the proximal to make a figure eight, and rotated over both K-wires. In order to provide good compression in the fracture line, a knot is made and tightened with pliers, and fixation is completed (Figure 4a, b). For better fixation, the proximal ends of the K-wires are bent and embedded in the triceps brachii tendon. The excess metal wire is twisted and cut to prevent skin irritation. After checking the implants and fracture line with fluoroscopy, the operation is completed.



**FIGURE 3.** (a) Standard posterior longitudinal approach with radial side curving we used in surgical treatment of olecranon fracture. (b) Intraoperative view of explored olecranon fracture.



**FIGURE 4.** (a) Anteroposterior X-ray of a 28-year-old male patient undergoing tension band wiring procedure due to olecranon fracture. (b) Lateral X-ray of a 28-year-old male patient undergoing tension band wiring procedure due to olecranon fracture.

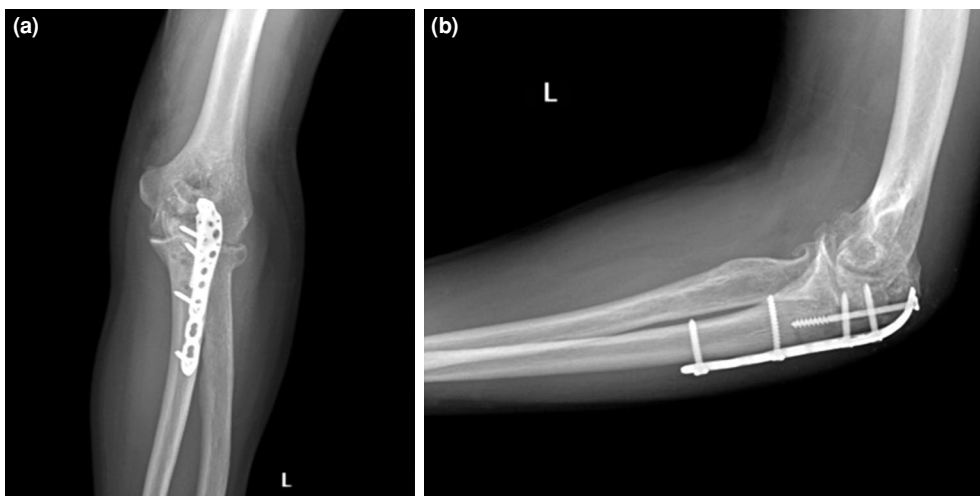
One advantage of the PF procedure is that it provides more stable fixation than TBW in cases of complex fractures.<sup>[5]</sup> In this procedure, after the fracture line is revealed, temporary fracture reduction is also provided with a bone clamp. Then, a 3.5-mm limited contact dynamic compression plate suitable for olecranon and proximal ulna anatomy is placed and fixation is completed with locking screws (Figure 5a, b). Proximal screws are placed unicortically to avoid intraarticular penetration. In addition, one locking screw is placed intramedullary from the tip of the olecranon to increase stability. After checking the implants and fracture line with fluoroscopy, the operation is completed.

A similar rehabilitation program was applied in both patient groups after surgery. All patients had

an adjustable-angle elbow orthosis and no angle restrictions. On the same day, passive movement was started to protect the ROM of all patients. All patients were discharged one day after surgery. Active flexion, extension, pronation, and supination were started for all patients at the end of the second week. At the end of the sixth week, the rehabilitation process of all patients was completed.

#### Statistical analysis

Statistical analysis was performed using the SPSS version 15.0 software (SPSS Inc., Chicago, IL, USA). Independent samples t-tests were used to evaluate parametric statistics and Mann-Whitney U tests were used to evaluate non-parametric statistics. Values of  $p < 0.05$  were accepted as statistically significant.



**FIGURE 5.** (a) Anteroposterior X-ray of a 44-year-old male patient undergoing plate fixation procedure due to olecranon fracture. (b) Lateral X-ray of a 44-year-old male patient undergoing plate fixation procedure due to olecranon fracture.



	TBW group			PF group			<i>p</i>
	n	%	Mean±SD	n	%	Mean±SD	
Age (year)			40.4±18.1			43.7±20.5	0.726
Sex							0.458
Male	24	55		27	56		
Female	20	45		21	44		
Follow-up (month)			39.3±16.8			37.2±17.6	0.623
Revisions (patient) (ratio)	6	14		1	2		0.335
Return to work (week)			9.2±3.1			7.8±2.6	0.279

TBW: Tension band wiring; PF: Plate fixation; SD: Standard deviation.

## RESULTS

Data on the demographic characteristics of the patients such as age, sex, mean follow-up, mean time to return to work, and revision rates are shown in Table I. Both groups had at least three years of follow-up. During this period, no patient had radiographic arthrosis or heterotopic ossification. Four patients in the TBW group and two patients in the PF group underwent revision surgery after six months due to radiographic nonunion. In revision surgery, all patients underwent fracture line debridement, autografting, and plate fixation with a different implant, and union was observed in all patients. These patients were evaluated one year after revision surgery. The mean DASH score was 13.6±2.1, the mean Mayo score was 78±8.6, and the mean flexion-extension ROM degree was 132.5±11.3° in patients undergoing revision surgery. In addition, although earlier time to return to work was observed in patients in the PF group when the treatment groups were compared, there was no statistically significant difference ( $p=0.279$ ).

The values of joint ROM measured by goniometer for all patients at a mean of one year after radiographic union are presented in Table II. At first, all elbow joint ROM measurements showed functional motion arcs of 30° to 130° of elbow extension/flexion and 50° pronation to 50° supination. After both procedures, residual deficit was detected in active flexion, extension, pronation, and supination. Active pronation and supination ROM were measured for both procedures and similar values were found. When elbow active flexion-extension ROM measurements were compared, a mean of 4° of difference was seen in favor of the PF group and this was statistically significant ( $p=0.043$ ). On the other hand, there was no significant difference in active pronation-supination ROM ( $p=0.257$ ).

Approximately one year after radiographic union, the elbow joint was evaluated functionally with the DASH score (range, 0 to 100) and the Mayo score (range, 0 to 100), and the data obtained are shown in Table III. A high DASH score shows poor results and

	TBW group	PF group	<i>p</i>
	Degree±SD	Degree±SD	
Mean extension deficit	5.3±2.1	2.8±1.8	0.385
Mean flexion deficit	5.0±2.2	3.5±1.9	0.426
Mean pronation deficit	0.6±0.2	0.3±0.2	0.752
Mean supination deficit	1.2±0.5	0.9±0.4	0.811
Mean flexion-extension ROM	139.8±7.3	143.8±5.8	0.043*
Mean pronation-supination ROM	98.3±1.2	98.8±0.8	0.257

TBW: Tension band wiring; PF: Plate fixation; SD: Standard deviation; ROM: Range of motion; \* Statistically significant.

TABLE III

Values of Disabilities of the Arm, Shoulder, and Hand and Mayo score

	TBW group	PF group	<i>p</i>
	Mean±SD	Mean±SD	
DASH score	10.0±1.8	7.7±1.2	0.001*
Mayo score	84.0±9.3	88.3±9.1	0.049*

TBW: Tension band wiring; PF: Plate fixation; SD: Standard deviation; DASH: Disabilities of the Arm, Shoulder, and Hand; \* Statistically significant.

a high Mayo score shows good results. Although they were close to each other, functionally more successful scores were calculated in the PF group. When the groups were compared, the differences were found to be statistically significant (DASH,  $p=0.001$ ; Mayo,  $p=0.043$ ).

Superficial infection developed in one patient in each group in the early period. After the patients applied to the hospital, wound debridement and irrigation were performed on the same day. *Staphylococcus epidermidis* growth occurred in wound cultures taken intraoperatively from these patients. According to the wound cultures, 3×100 mg oral amoxicillin+clavulanate treatment was given for three weeks by infectious diseases clinic to both patients. Both of the patients recovered without the need for implant removal. In addition, due to skin irritation by the implants, 26 (59%) patients in the TBW group and four (8%) patients in the PF group underwent implant removal within one year of radiographic union.

## DISCUSSION

In many previous studies, it has been stated that TBW gives very good results in cases of simple olecranon fractures and is an appropriate treatment.<sup>[7,16]</sup> In addition, the implants used in TBW treatment are cheaper. In a retrospective study by Tan et al.,<sup>[17]</sup> TBW was found to have lower costs than PF in the treatment of 147 patients with Mayo type 2A olecranon fractures. However, some complications related to the implants used in TBW procedures have been reported. These implants cause skin irritation in 40 to 90% of cases, which is a source of serious discomfort for patients.<sup>[18]</sup> Due particularly to the proximal migration of K-wires, 60 to 80% of patients have to undergo secondary surgery for implant removal.<sup>[19]</sup> According to a systematic review and meta-analysis, lower complication rates and fewer implant removals were detected in cases of PF.<sup>[20]</sup> The comparison made by Powell et al.<sup>[21]</sup> found that complication and reoperation rates were lower in the

PF group and that the difference was statistically significant. In another study by Hume and Wiss,<sup>[22]</sup> metal prominence was observed in 42% of patients who underwent TBW. In our study, 26 (59%) patients undergoing TBW procedures underwent secondary operations due to implant irritation within one year after radiographic union. In the PF group, only four (8%) patients underwent implant removal for the same reason. Secondary surgery performed due to implant removal in TBW treatment stands out as the biggest handicap of this treatment.

One of the main goals of surgery in olecranon fractures is to start joint ROM exercises as soon as possible in the postoperative period and to minimize residual motion restriction.<sup>[23]</sup> Fifteen patients who underwent plate fixation due to olecranon fractures were followed-up by Inui et al.<sup>[24]</sup> for a mean of 14 months, and a mean of 11° of extension deficit and 133° of flexion were measured, with 122° of joint flexion-extension ROM being calculated. Even if deficit was detected in the extension movement, similar values were found in previous studies.<sup>[25]</sup> In our study, the flexion-extension ROM measurements obtained after both procedures were found to be between 30° and 130°, which is the functional elbow joint ROM.<sup>[26]</sup> Although there were very good results for both procedures, greater flexion-extension ROM by 4° was measured after the PF procedure and this difference was found to be statistically significant. Excellent results were obtained for pronation-supination ROM and no significant difference was observed between the two procedures.

Many scales are used in research to evaluate functional results after elbow surgery. The DASH and Mayo scores are the most preferred and most reliable ones, and they have an important place in the evaluation of olecranon fractures following operation. In a study conducted by Gathen et al.,<sup>[5]</sup> the DASH and Mayo scores were applied to compare the TBW and PF procedures in cases of olecranon fractures and no significant difference was found between the two procedures. Furthermore, in a systematic review and meta-analysis conducted by Ren et al.,<sup>[27]</sup> no significant difference was found between TBW and PF procedures in terms of DASH score, improvement rate, joint ROM, operation time, and blood loss. In our study evaluating both procedures functionally with the DASH and Mayo scores, better scores were obtained in the group treated with PF, and a statistically significant difference was detected.

Biomechanical studies on cadavers also play an important role in the evaluation of implant

stability and survival. In a study by Gordon et al.<sup>[28]</sup> on cadavers, plate fixation was applied to olecranon fracture models and very good results were reported in terms of function. In olecranon fractures, TBW and PF procedures were applied by Midtgaard et al.,<sup>[29]</sup> a biomechanical comparison was performed on cadavers and no significant difference was observed in terms of fracture displacement between the groups. However, 80% implant failure was detected after the TBW procedure and only 10% following the PF procedure; the twisted point of the metal wire was determined as the weakest point of fixation. In another biomechanical study, the rates of interfragmentary compression and immobility in the fracture line were found to be higher in the PF group.<sup>[30]</sup> In addition, plate fixations with locked screws are reported to be more resistant to repeated loads. Similarly, in patients undergoing TBW procedures, radiographic loss of reduction and articular step-off were observed more frequently compared to PF.<sup>[21]</sup> In our study, six (14%) patients who underwent the TBW procedure had nonunion due to implant failure and later underwent revision surgery. In patients undergoing revision surgery, it was found that the metal wire was broken or the twist was loosened. Only one (2%) patient undergoing the PF procedure needed revision surgery and implant failure was not detected in this patient. We think that the hardware failure rate was higher as a result of cyclic loads in the TBW procedure. Although it was not statistically significant, shorter time to return to work in the PF group may have been due to the patient feeling safe as a result of implant stability.<sup>[31]</sup>

There are some limitations of our study. Since it was primarily a retrospective study, there were data limitations. Although the number of cases was relatively sufficient, longer follow-up times are needed for better results. Another limitation is that the joint ROM measurements were performed manually and so there is a possibility of error. In addition, the scales used in the functional evaluation were filled in according to the patient's statements and may thus show subjective results. There is no standard scale of analysis to evaluate both procedures more objectively.

In conclusion, we have compared two procedures that are preferred as standards in the treatment of olecranon fractures clinically and functionally. Satisfactory functional results were obtained after both procedures. The PF group had greater flexion-extension ROM, an earlier return to work, and lower revision rates. Although the TBW procedure is low-cost, it poses a serious challenge for orthopedic

surgeons in terms of implant irritation. Many factors including the patient's bone quality, the fracture pattern, and the surgeon's preference play a role in determining which procedure is more appropriate.

#### Declaration of conflicting interests

The authors declared no conflicts of interest with respect to the authorship and/or publication of this article.

#### Funding

The authors received no financial support for the research and/or authorship of this article.

## REFERENCES

1. Kuru T, Mutlu İ. Suture anchor fixation may be an alternative to tension band wiring in olecranon fractures: Finite element analysis. *Jt Dis Relat Surg* 2020;31:238-45.
2. Gierer P, Wichelhaus A, Rotter R. Fractures of the olecranon. *Oper Orthop Traumatol* 2017;29:107-14.
3. Powell AJ, Farhan-Alanie OM, Bryceland JK, Nunn T. The treatment of olecranon fractures in adults. *Musculoskelet Surg* 2017;101:1-9.
4. Wilkerson JA, Rosenwasser MP. Surgical techniques of olecranon fractures. *J Hand Surg Am* 2014;39:1606-14.
5. Gathen M, Jaenisch M, Peez C, Weinhold L, Schmid M, Welle K, et al. Plate fixation and tension band wiring after isolated olecranon fracture comparison of outcome and complications. *J Orthop* 2019;18:69-75.
6. van der Linden SC, van Kampen A, Jaarsma RL. K-wire position in tension-band wiring technique affects stability of wires and long-term outcome in surgical treatment of olecranon fractures. *J Shoulder Elbow Surg* 2012;21:405-11.
7. Chalidis BE, Sachinis NC, Samoladas EP, Dimitriou CG, Pournaras JD. Is tension band wiring technique the "gold standard" for the treatment of olecranon fractures? A long term functional outcome study. *J Orthop Surg Res* 2008;3:9.
8. Duckworth AD, Clement ND, White TO, Court-Brown CM, McQueen MM. Plate versus tension-band wire fixation for olecranon fractures: A prospective randomized trial. *J Bone Joint Surg [Am]* 2017;99:1261-73.
9. Flinterman HJ, Doornberg JN, Guitton TG, Ring D, Goslings JC, Kloen P. Long-term outcome of displaced, transverse, noncomminuted olecranon fractures. *Clin Orthop Relat Res* 2014;472:1955-61.
10. Gruszka D, Arand C, Greenfield J, Nowak TE, Kuechle R, Kuhn S, et al. Is the novel olecranon tension plate a valid alternative to tension band wiring of olecranon fractures? A biomechanical study on cadaver bones. *Arch Orthop Trauma Surg* 2017;137:1651-8.
11. Lovy AJ, Levy I, Keswani A, Rubin T, Hausman MR. Outcomes of displaced olecranon fractures treated with the Olecranon Sled. *J Shoulder Elbow Surg* 2018;27:393-7.
12. Schliemann B, Raschke MJ, Groene P, Weimann A, Wähnert D, Lenschow S, et al. Comparison of tension band wiring and precontoured locking compression plate fixation in Mayo type IIA olecranon fractures. *Acta Orthop Belg* 2014;80:106-11.
13. Gummesson C, Atroshi I, Ekdahl C. The disabilities of the arm, shoulder and hand (DASH) outcome questionnaire: longitudinal construct validity and measuring self-rated health change after surgery. *BMC Musculoskelet Disord* 2003;4:11.

14. Macko D, Szabo RM. Complications of tension-band wiring of olecranon fractures. *J Bone Joint Surg [Am]* 1985;67:1396-401.
15. Prayson MJ, Iossi MF, Buchalter D, Vogt M, Towers J. Safe zone for anterior cortical perforation of the ulna during tension-band wire fixation: a magnetic resonance imaging analysis. *J Shoulder Elbow Surg* 2008;17:121-5.
16. Huang TW, Wu CC, Fan KF, Tseng IC, Lee PC, Chou YC. Tension band wiring for olecranon fractures: relative stability of Kirschner wires in various configurations. *J Trauma* 2010;68:173-6.
17. Tan BY, Pereira MJ, Ng J, Kwek EB. The Ideal Implant for Mayo 2A Olecranon Fractures? An Economic Evaluation Ideal Implant Mayo 2A Olecranon Fracture (short form running title). *J Shoulder Elbow Surg* 2020:S1058-2746(20)30480-8.
18. Carofino BC, Santangelo SA, Kabadi M, Mazzocca AD, Browner BD. Olecranon fractures repaired with FiberWire or metal wire tension banding: a biomechanical comparison. *Arthroscopy* 2007;23:964-70.
19. Snoddy MC, Lang MF, An TJ, Mitchell PM, Grantham WJ, Hooe BS, et al. Olecranon fractures: factors influencing re-operation. *Int Orthop* 2014;38:1711-6.
20. Koziarz A, Woolnough T, Oitment C, Nath S, Johal H. Surgical management for olecranon fractures in adults: A systematic review and meta-analysis. *Orthopedics* 2019;42:75-82.
21. Powell AJ, Farhan-Alanie OM, McGraw IWW. Tension band wiring versus locking plate fixation for simple, two-part Mayo 2A olecranon fractures: a comparison of post-operative outcomes, complications, reoperations and economics. *Musculoskelet Surg* 2019;103:155-60.
22. Hume MC, Wiss DA. Olecranon fractures. A clinical and radiographic comparison of tension band wiring and plate fixation. *Clin Orthop Relat Res* 1992;285:229-35.
23. Dawson J, Doll H, Boller I, Fitzpatrick R, Little C, Rees J, et al. The development and validation of a patient-reported questionnaire to assess outcomes of elbow surgery. *J Bone Joint Surg [Br]* 2008;90:466-73.
24. Inui A, Kuroda T, Kurosawa T, Kokubu T, Mifune Y, Nishimoto H, et al. Case series of comminuted olecranon fracture treated by plate fixation; do we have to remove the plate? *Kobe J Med Sci* 2018;64:E115-E8.
25. De Giacomo AF, Tornetta P 3rd, Sinicrope BJ, Cronin PK, Althausen PL, Bray TJ, et al. Outcomes after plating of olecranon fractures: A multicenter evaluation. *Injury* 2016;47:1466-71.
26. Sardelli M, Tashjian RZ, MacWilliams BA. Functional elbow range of motion for contemporary tasks. *J Bone Joint Surg [Am]* 2011;93:471-7.
27. Ren YM, Qiao HY, Wei ZJ, Lin W, Fan BY, Liu J, et al. Efficacy and safety of tension band wiring versus plate fixation in olecranon fractures: a systematic review and meta-analysis. *J Orthop Surg Res* 2016;11:137.
28. Gordon MJ, Budoff JE, Yeh ML, Luo ZP, Noble PC. Comminuted olecranon fractures: a comparison of plating methods. *J Shoulder Elbow Surg* 2006;15:94-9.
29. Midtgaard KS, Søreide E, Brattgjerd JE, Moatshe G, Madsen JE, Flugsrud GB. Biomechanical comparison of tension band wiring and plate fixation with locking screws in transverse olecranon fractures. *J Shoulder Elbow Surg* 2020;29:1242-8.
30. Wilson J, Bajwa A, Kamath V, Rangan A. Biomechanical comparison of interfragmentary compression in transverse fractures of the olecranon. *J Bone Joint Surg [Br]* 2011;93:245-50.
31. Atik OŞ. Is there something new and interesting in my article?. *Eklemler Hastalıkları Cerrahisi*. 2019;30:69.