



A rare cause of osteomyelitis of distal phalanx: *Candida lusitanae*

Erdinc Acar, MD¹, Ugur Bezirgan, MD¹

Department of Orthopedics and Traumatology, Hand and Upper Extremity Surgery Division, Ankara City Hospital, Ankara, Turkey

Osteomyelitis of the metacarpal bones and phalanges accounts for about 1.1 to 10% of hand infections.^[1-4] In the majority of cases with phalangeal osteomyelitis, distal phalanx is the most frequently involved bone.^[1] In the literature, osteomyelitis of the phalanges caused by the *Candida* species (spp.) is rare and many culprits play a role in the development of osteomyelitis;^[5,6] however, it is a difficult-to-treat condition with a high morbidity rate. Among *Candida* spp., *Candida albicans* is the most common cause of osteomyelitis.^[7,8] Osteomyelitis caused by other *Candida* spp. have been described in case reports in the literature.^[9] On the other hand, *Candida lusitanae* (*C. lusitanae*) is an uncommon pathogen in osteomyelitis.^[10] Risk factors associated with *C. lusitanae* infection include neutropenia, post-trauma, hematological malignancies, the use of cytotoxic drugs or corticosteroids, and the receipt of broad-spectrum antibiotics or central venous catheters.^[1,11]

Received: October 12, 2020

Accepted: December 08, 2020

Published online: December 21, 2021

Correspondence: Erdinç Acar, MD, Ankara Şehir Hastanesi Ortopedi ve Travmatoloji Kliniği, El ve Üst Ekstremitte Cerrahisi Bölümü, 06800 Çankaya, Ankara, Türkiye.

E-mail: erdal240@gmail.com

Doi: 10.5606/ehc.2021.79490

Citation: Acar E, Bezirgan U. A rare cause of osteomyelitis of distal phalanx: *Candida lusitanae*. Jt Dis Relat Surg 2021;32(x):i-iv.

©2021 All right reserved by the Turkish Joint Diseases Foundation

This is an open access article under the terms of the Creative Commons Attribution-NonCommercial License, which permits use, distribution and reproduction in any medium, provided the original work is properly cited and is not used for commercial purposes (<http://creativecommons.org/licenses/by-nc/4.0/>).

ABSTRACT

Osteomyelitis of the phalanx caused by *Candida* species are rare. A 49-year-old female patient was admitted to an external center with a splinter injury of the third phalanx of the middle finger of her left hand about 45 days ago. She was referred to our clinic with persistent pain and discharge, despite four-week antibiotherapy. Debridement and curettage were performed and partial excision of the distal phalanx at an appropriate level was done. Her complaints gradually resolved postoperatively with prescribed antibiotics for the pathogen identified as *Candida lusitanae* based on the intraoperative cultures. At her three-month follow-up visit, treatment yielded near-excellent results. To the best of our knowledge, this is the first case of osteomyelitis of the distal phalanx caused by *Candida lusitanae* in the literature, highlighting the importance of definitive diagnosis and pathogen-specific treatment, rather than empirical treatment, to achieve favorable results with cure.

Keywords: Antibiotherapy, *candida lusitanae*, debridement, distal phalanx, osteomyelitis.

Treatment of osteomyelitis mainly involves early diagnosis, adequate antibiotherapy, and surgery. The latter has a wide range of procedures including debridement, curettage, arthrodesis, joint reconstruction, and amputation.^[1,12,13] In this report, we present the first case of osteomyelitis of the distal phalanx caused by *C. lusitanae* in the literature and discuss its diagnosis and treatment in the light of current data.

CASE REPORT

A 49-year-old female patient was admitted to an external center with a splinter injury (piece of wood) of the third phalanx of the middle finger of her left hand about 45 days ago. She was referred to our clinic with persistent pain and discharge, despite four-week antibiotherapy (amoxicillin/clavulanic acid 1000 mg, PO, b.i.d.) (Figure 1). Laboratory test results were as follows: white blood cell (WBC) count 11,750 (3,900-10,200)/mm³, erythrocyte

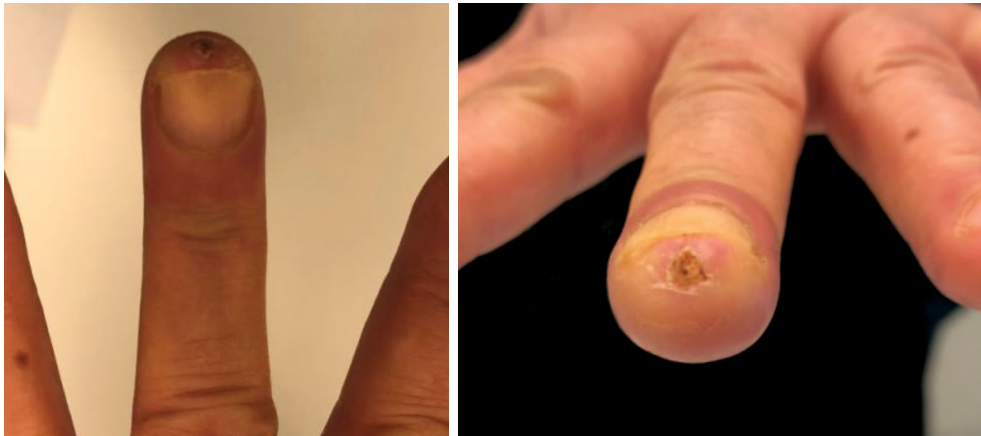

FIGURE 1. Splinter injury of the third phalanx of middle finger of left hand with pain and discharge.

sedimentation rate (ESR) 17 (0-20) mm/h, and C-reactive protein (CRP) 0.000785 (0-0,005) g/L. Physical examination and radiographs revealed osteomyelitis of the distal phalanx (Figure 2). Severe tenderness over the distal volar pulp on palpation and minimal discharge from the entry site of the splinter. Surgical treatment was decided, and a written informed consent was obtained from the patient.

Surgery and follow-up were performed by two hand surgeons of our clinic. During surgery, debridement and curettage were performed, and partial excision of the distal phalanx at an appropriate level was done (Figure 3). Postoperative radiographs confirmed the partial excision of the distal phalanx at an appropriate level (Figure 4). Gram staining of the specimens collected intraoperatively

showed an abundant number of neutrophils (polymorphonuclear neutrophil leukocytes) with no microorganism. Bacterial and fungal cultures were incubated and regular-shaped colonies with white to cream color were seen at 72 h of incubation in the blood agar and sabouraud dextrose agar. Using the matrix-assisted laser desorption/ionization time of flight mass spectrometry (MALDI-TOF-MS; VITEK®; bioMérieux Diagnostics, France), *C. lusitaniae* was isolated. The antifungal susceptibility was tested via the VITEK® 2 (bioMérieux Diagnostics, France) antimicrobial susceptibility testing. The culture analysis showed production of *C. lusitaniae* and the pathological examination result was reported as superficial tissue characterized by parakeratosis and squamous hyperplasia. Postoperative laboratory testing showed normal ESR and CRP levels with a

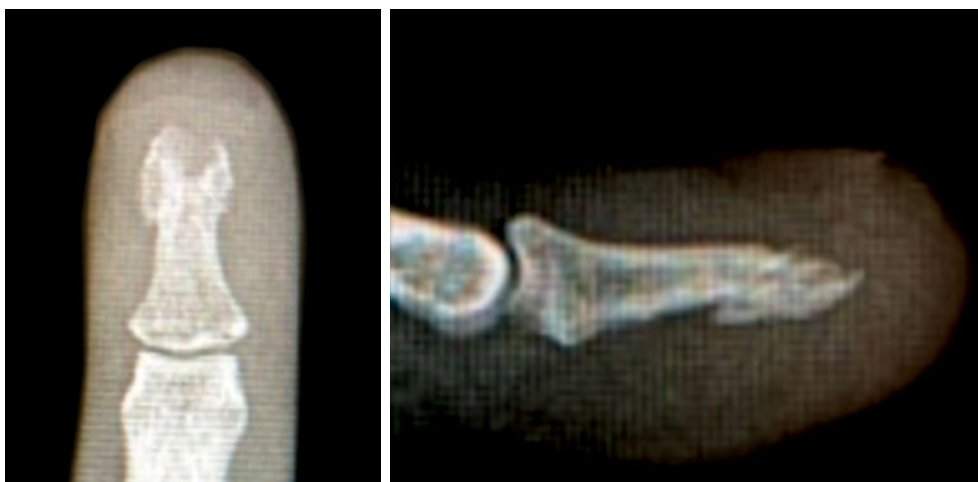

FIGURE 2. Anteroposterior and lateral radiographs showing local osteolysis due to osteomyelitis of distal phalanx.

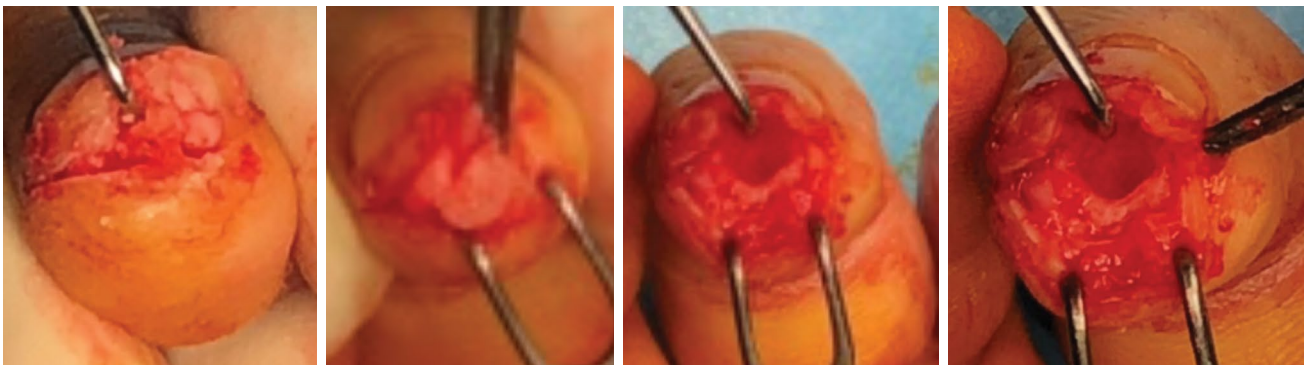


FIGURE 3. An intraoperative view of debridement and curettage with partial excision of distal phalanx.

WBC count of 9,500/mm³. The patient was consulted to the infectious diseases clinic and fluconazole 100 mg Po (Triflucan®, Pfizer İlaçları Ltd. Şti., Istanbul, Turkey) for three weeks was initiated. Wound dressing was applied every three days and sutures were removed at three weeks. During follow-up visits at three and six weeks, and three months, near-excellent results were achieved. At the end of three months, physical examination revealed full active range of motion of the phalangeal joint. The patient is still free from pain or discharge on later follow-up visits.

The patient and/or her family were informed that data from the case would be submitted for publication and gave their consent.

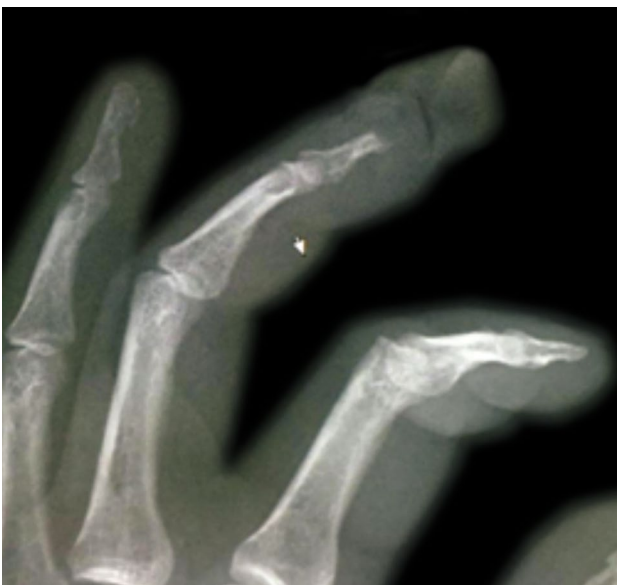

FIGURE 4. A postoperative oblique radiograph confirming the partial excision of distal phalanx at an appropriate level.

DISCUSSION

Candida osteomyelitis of the bones has been very rarely reported in the literature.^[14,15] There are also case reports of osteomyelitis of the distal phalanges.^[16,17] In the literature, the first case of osteomyelitis of the distal humerus caused by *C. lusitaniae* was a premature infant.^[18] In addition, a case series of Candida osteomyelitis including 207 pediatric and adult patients was previously reported; however, the involvement site of osteomyelitis was undetermined.^[8] There are also several case reports of olecranon bursitis and septic arthritis caused by *C. lusitaniae*.^[19,20] To the best of our knowledge, our case is the first case of osteomyelitis of the distal phalanx caused by *C. lusitaniae* in the literature in which its diagnosis and treatment were discussed in detail.^[21]

In the majority of cases, laboratory testing yields non-specific results with slightly elevated ESR and CRP levels, and leukocytosis in only 35% of patients.^[22,23] In addition, plain radiography typically shows bone tissue alterations such as periosteal reaction and destruction 10 to 12 days after the infection.^[24] Although combination therapy of voriconazole and posaconazole can be used in the treatment of infections caused by *C. lusitaniae*^[25] fluconazole 6 mg/kg for six weeks is usually administered.^[26] In our case, similarly, pre- and postoperative ESR and CRP levels were normal. However, the preoperative WBC count increased, while it tended to decrease after surgery. Fortunately, plain radiographs demonstrated specific findings compatible with *C. lusitaniae* infections, since the patient was admitted to our clinic about 45 days after the injury. Unlike the literature, however, the fluconazole treatment was recommended by the infectious diseases clinic for three weeks. During follow-up in the outpatient setting, no pain or

discharge was observed, which underscores the use of adequate antibiotherapy in our case.

In conclusion, osteomyelitis should be considered in patients with splinter injuries suffering from persistent pain and discharge despite long-term antibiotic use. This case is the first report of osteomyelitis of the distal phalanx caused by *C. lusitaniae* in the literature, highlighting the importance of definitive diagnosis and pathogen-specific treatment, rather than empirical treatment, to achieve favorable results with cure.

Declaration of conflicting interests

The authors declared no conflicts of interest with respect to the authorship and/or publication of this article.

Funding

The authors received no financial support for the research and/or authorship of this article.

REFERENCES

1. Reilly KE, Linz JC, Stern PJ, Giza E, Wyrick JD. Osteomyelitis of the tubular bones of the hand. *J Hand Surg Am* 1997;22:644-9.
2. Waldvogel FA, Medoff G, Swartz MN. Osteomyelitis: a review of clinical features, therapeutic considerations and unusual aspects. *N Engl J Med* 1970;282:198-206.
3. Stone NH, Hirsch H, Humphrey CR, Boswick JA Jr. Empirical selection of antibiotics for hand infections. *J Bone Joint Surg [Am]* 1969;51:899-903.
4. Gürbüz K. The treatment of onychogryphosis of hand nails by total matricectomy and dorsal V-Y advancement flap. *Jt Dis Relat Surg* 2020;31:39-42.
5. Jaime-Villalonga A, Saul Z, Miljkovic G. Mycobacterium arupense finger osteomyelitis: Case report. *Int J Infect Dis* 2020;92:226-7.
6. Raval P. Phalangeal Osteomyelitis Caused by Staphylococcus lugdunensis - A Case Report of a Rare Association and Review of Literature. *J Orthop Case Rep* 2019;9:70-3.
7. Slenker AK, Keith SW, Horn DL. Two hundred and eleven cases of Candida osteomyelitis: 17 case reports and a review of the literature. *Diagn Microbiol Infect Dis* 2012;73:89-93.
8. Gamaletsou MN, Kontoyiannis DP, Sipsas NV, Moriyama B, Alexander E, Roilides E, et al. Candida osteomyelitis: analysis of 207 pediatric and adult cases (1970-2011). *Clin Infect Dis* 2012;55:1338-51.
9. Lopez R, Hunter AR, Geoghegan O, Demertzi E. Candida parapsilosis osteomyelitis. *BMJ Case Rep* 2014;2014:bcr2014206520.
10. Viudes A, Pemán J, Cantón E, Salavert M, Ubeda P, López-Ribot JL, et al. Two cases of fungemia due to Candida lusitaniae and a literature review. *Eur J Clin Microbiol Infect Dis* 2002;21:294-9.
11. Merz WG. Candida lusitaniae: frequency of recovery, colonization, infection, and amphotericin B resistance. *J Clin Microbiol* 1984;20:1194-5.
12. Ono R, Komura S, Hirakawa A, Hirose H, Tsugita M, Masuda T, et al. Staged arthrodesis using the Masquelet technique for osteomyelitis of the finger with articular destruction: a report of two cases. *Arch Orthop Trauma Surg* 2019;139:1025-31.
13. Pruzansky ME, Lee Y, Pruzansky J. Masquelet Technique for Phalangeal Reconstruction and Osteomyelitis. *Tech Hand Up Extrem Surg* 2020. [Online ahead of print]
14. McLeod N, Fisher M, Lasala PR. Vertebral osteomyelitis due to Candida species. *Infection* 2019;47:475-8.
15. Arias F, Mata-Essayag S, Landaeta ME, Capriles CH, Pérez C, Núñez MJ, et al. Candida albicans osteomyelitis: case report and literature review. *Int J Infect Dis* 2004;8:307-14.
16. Toki S, Hibino N, Sairyō K, Takahashi M, Yoshioka S, Yamano M, et al. Osteomyelitis Caused by Candida glabrata in the Distal Phalanx. *Case Rep Orthop* 2014;2014:962575.
17. Schmutz N, Adler T, Schelhorn N, Wirz S, Fricker R. Postoperative Osteomyelitis of a Distal Phalanx Caused by Raoultella ornithinolytica. *Handchir Mikrochir Plast Chir* 2016;48:175-8.
18. Oleinik EM, Della-Latta P, Rinaldi MG, Saiman L. Candida lusitaniae osteomyelitis in a premature infant. *Am J Perinatol* 1993;10:313-5.
19. Behar SM, Chertow GM. Olecranon bursitis caused by infection with Candida lusitaniae. *J Rheumatol* 1998;25:598-600.
20. Bariola JR, Saccente M. Candida lusitaniae septic arthritis: case report and review of the literature. *Diagn Microbiol Infect Dis* 2008;61:61-3.
21. Atik OŞ. Is there something new and interesting in my article? *Eklemler Hastalıkları Cerrahisi* 2019;30:69.
22. Grimby C, Odenbach J, Vandermeer B, Forgie S, Curtis S. Parenteral and oral antibiotic duration for treatment of pediatric osteomyelitis: a systematic review protocol. *Syst Rev* 2013;2:92.
23. Couto-Gonzalez I, Brea-García B, Taboada-Suárez A. Purulent infection in the third finger with associated osteomyelitis. *BMJ Case Rep* 2013;2013:bcr2012008476.
24. Ferroni A, Al Khoury H, Dana C, Quesne G, Berche P, Glorion C, et al. Prospective survey of acute osteoarticular infections in a French paediatric orthopedic surgery unit. *Clin Microbiol Infect* 2013;19:822-8.
25. Sanchis M, Guarro J, Sutton DA, Fothergill AW, Wiederhold N, Capilla J. Voriconazole and posaconazole therapy for experimental Candida lusitaniae infection. *Diagn Microbiol Infect Dis* 2016;84:48-51.
26. Pappas PG, Rex JH, Sobel JD, Filler SG, Dismukes WE, Walsh TJ, et al. Guidelines for treatment of candidiasis. *Clin Infect Dis* 2004;38:161-89.